



# Short- and Long-Term Outcomes of Vertical Banded Gastroplasty Converted to Roux-en-Y Gastric Bypass

Peter Vasas · Bruno Dillemans ·  
Sebastiaan Van Cauwenberge ·  
Marieke De Visschere · Charlotte Vercauteren

© Springer Science+Business Media New York 2012

## Abstract

**Background** Vertical banded gastroplasty (VBG) often necessitates revisional surgery for weight regain or symptoms related to gastric outlet obstruction. Roux-en-Y gastric bypass (RYGB) is considered as the revisional procedure of choice. However, revisional bariatric surgery is associated with relatively higher rates of complications. The aim of the current study is to analyse our single-centre experience with patients requiring revisional RYGB following primary VBG.

**Methods** Retrospective review of the prospectively collected database identified 153 patients who underwent RYGB as a revisional procedure after VBG from Feb 2004–Feb 2011. Early and late complications, weight data and resolution of symptoms related to gastric outlet obstruction were analysed. **Results** One hundred twenty-three females and 30 males underwent revisional RYGB post VBG. Mean age was 44.4 (15–74) years with a mean pre-operative body mass index (BMI) of 34.2 (23.5–65.5) kg/m<sup>2</sup>. Mean hospital stay was 4.3 days. Early complication rate was 3.9 % with a 30-day re-operation rate of 1.3 %. Mortality and leak rate were zero. After a mean follow-up of 48 months, the mean BMI decreased significantly to 28.8 kg/m<sup>2</sup> and a complete resolution of the obstructive symptoms was achieved in nearly all patients. Late complications developed in 11 (7.7 %) of the patients of which seven (4.9 %) required surgery.

**Conclusions** Revisional RYGB following VBG is technically challenging but safe with low rates of morbidity and

mortality, comparable to primary RYGB. It produces a significant reduction in body weight and in symptoms resolution. We recommend RYGB as the procedure of choice in patients requiring revisional surgery following VBG.

**Keywords** Vertical banded gastroplasty · VBG · Revisional bariatric surgery · Roux-en-Y gastric bypass

## Introduction

Morbid obesity is a major and furthermore increasing health problem worldwide and currently only bariatric surgery provide long-term effective treatment. An increasing number of bariatric procedures are performed each year, and the number of patients requiring revisional procedures is also increasing. Vertical banded gastroplasty (VBG) used to be a common restrictive bariatric procedure in the 1990s, but nowadays it is out from the bariatric surgeons' repertoire due to its late complications (band erosion and stenosis) and insufficient long-term weight loss [1]. Balsiger et al. reported the Mayo clinic 10-year results after VBG with disappointing results: 79 % failure rate [2]. Considering that the requirement for revisional surgery after VBG is 10–65 %, and the revisional operation could follow the primary procedure with 10–23 years one could expect an increasing number of patient presenting for revisional surgery [3–7].

The VBG is a restrictive procedure, originally described by Mason in 1982 [8]. The procedure was performed via laparotomy and a neo-pylorus was constructed with a Dacron or Marlex mesh. The stomach was stapled but not transected resulting in the long-term 65 % staple line failure rate (gastro-gastric fistula) [6, 7]. MacLean revised the procedure and performed it laparoscopically with a complete transection of the stomach [9]. This significantly reduced the risk of the staple line failure and the development of

P. Vasas · B. Dillemans (✉) · S. Van Cauwenberge ·  
M. De Visschere · C. Vercauteren  
Department of Bariatric Surgery,  
AZ Sint Jan Brugge-Oostende AV,  
Bruges, Belgium  
e-mail: Bruno.Dillemans@azsintjan.be

P. Vasas  
e-mail: vasasdr@gmail.com

gastro-gastric fistula, which inevitable leads to weight gain. Furthermore, at the end of the gastric pouch the Dacron/Marlex mesh was replaced by a small silastic ring. The procedure is deemed to be restrictional; however, this effect fades after years as patients' eating habit usually changes to maladaptive eating caused by gastric outlet obstruction. Patients have the tendency to adopt a high-caloric liquid diet which easily passes through the narrowed neo-pylorus junction resulting in insufficient weight loss or weight regain.

In many VBG patients, this narrowing or sometimes kinking of the neo-pylorus caused a progressive gastric outlet obstruction with medically untreatable vomiting, dysphagia or reflux as a result. Revisional options focusing on the treatment of the gastric outlet obstruction include a simple silastic ring removal (in case of a MacLean) or a longitudinal section of the Dacron/Marlex mesh in case of a Mason. Rarely, a complete restoration of the normal anatomy via gastro-gastrostomy is necessary. Disadvantage of those operations is that they do not solve the weight regain which is often concomitant or has the risk to reinstall otherwise [3, 10]. The preferred surgical salvage operation after failed restrictive procedures including the VBG is the Roux-en-Y gastric bypass (RYGB) [11–13]. This procedure has been shown to be the most effective in achieving a substantial and sustainable weight loss with improved obesity-related comorbidities and is currently still considered as the gold standard in bariatric surgery.

Previous studies have been performed to evaluate the revisional surgery outcome after failed VBG, but just few include a substantial number of patients or focus on the long-term weight loss data or complications [1, 14]. The aim of this single-centre study on 153 patients is to examine the safety and the efficacy on the short and on the long-term of the RYGB as a revisional procedure for failed VBG.

## Patient and Methods

### Study Design and Preoperative Work-Up

Retrospective analysis of the prospectively collected data from our institutional database was performed. All patients with a prior VBG who underwent a revisional bariatric procedure were identified, regardless whether the original operation was open (Mason) or laparoscopic (MacLean) and whether performed at our institute or in another hospital. Perioperative outcomes and detailed weight data (BMI) changes including the pre-VBG, post-VBG, pre-RYGB and post-RYGB status have been obtained via outpatient follow-up or direct telephone calls.

The failure of the previous VBG in terms of weight evolution was defined as less than 50 % excess weight loss

or a residual BMI  $\geq 35$ . Other indications for conversion were gastric outlet obstruction with intractable gastrointestinal (GI) symptoms (dysphagia, vomiting, severe gastro-oesophageal reflux (GORD)).

All patients underwent upper GI endoscopy with *Helicobacter pylori* testing +/- eradication and upper GI contrast studies as part of their preoperative evaluation. The aims of these studies were to evaluate the altered gastric anatomy, to locate the stricture or kinking at the level of the ring/mesh, to determine the pouch construction/size and to exclude gastro-gastric fistula. Detailed dietary history was obtained by a bariatric dietician in all cases and patients were required to keep food logs for review. Assessment by the multidisciplinary team was carried out prior to each operation and the revisional procedure was performed upon their approval.

### Surgical Procedure

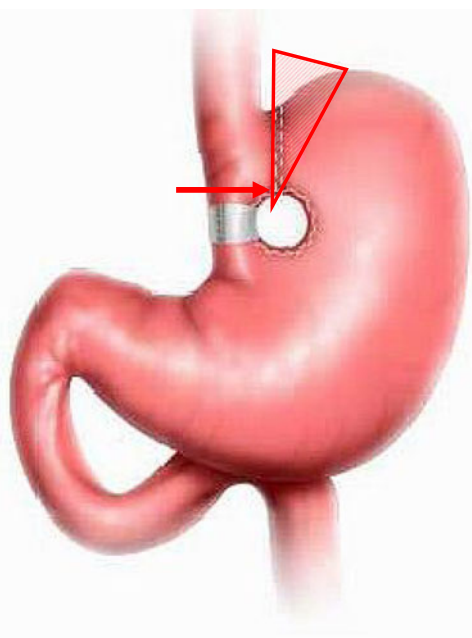
#### Initiation

All procedures were performed laparoscopically, under antibiotic prophylaxis. Pneumoperitoneum was established after Verress needle insertion. The procedure began with perigastric adhesiolysis with scissors or ultrasonic shears. This part of the operation was often time consuming, but after careful dissection, the ring or mesh could be identified in all cases, unless they had been removed or cut previously. The silastic ring was always removed; however, no effort was made to remove the Dacron/Marlex mesh.

#### Pouch Creation

The first step in the gastric pouch creation was to transect the stomach horizontally with a 60-mm-long thick linear stapler perpendicular to the lesser curve, well above the previous ring/mesh-site where the tissues appeared healthy and the circulation is not impaired from scarring.

1. In the case the original procedure was a Mason procedure and the pouch was dilated, a complete pouch reconstruction with complete resection of the staple line was performed (Fig. 1). The vertical part of the gastric pouch was created with one to two 60-mm-long stapler cartridges. In most cases, a staple height of 4.8 mm was used, depending on the thickness of the tissues and the level of scarring. Staple line reinforcement was never used for the procedures.
2. When the original procedure was a MacLean-procedure with divided staple lines between the pouch and the remnant stomach, the situation is slightly different. In most cases, there were some adhesions between the staple lines that can be easily divided. Only in the case of pouch dilatation that the staple lines were completely



**Fig. 1** RYGB pouch creation after an open VBG (Mason). The *red arrow* indicates the horizontal transection above the Marlex/Dacron mesh. The *striped triangle* represents the subtotal gastrectomy with resection of the staple line

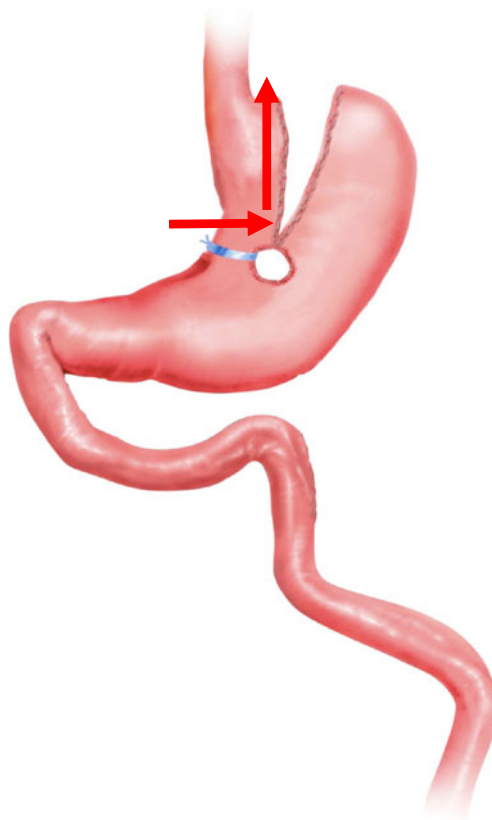
divided from each other and a pouch trimming was performed without the need to perform a subtotal gastrectomy (Fig. 2).

#### Completion of the Procedure

The gastro-jejunostomy was created by using a 25-mm-diameter circular stapler inserted via the abdominal wall. Staple height was adapted according to the thickness of the gastric tissue (Covidien DST series™ EEA™ 25 mm with mostly 4.8-mm staple height). The alimentary limb was antecolicly pulled up and measured to a length of 130 cm. The bypassed jejunum length was increased to 200 cm if the BMI was above 50. The jejuno-jejunostomy was constructed in a fully stapled manner. Intraoperative methylene blue leak test was carried out in each case. We started to close the Petersen's space from March 2008 except in cases where a lot of adhesions were present from previous VBG or other surgery. We do not routinely close the mesenterial defect at the jejuno-jejunostomy level. Our fully stapled standardized laparoscopic RYGB technique has been extensively described in a previous paper [15, 16].

#### Postoperative Care and Follow-Up

On the first postoperative day, patients were kept nil by mouth. No routine upper GI imaging series were performed. Oral intake was restarted on the second postoperative day and the patients were discharged not earlier than the third postoperative day with specific dietary instructions. To prevent deep venous



**Fig. 2** RYGB pouch creation after a laparoscopic VBG (MacLean). The *red arrows* indicate the horizontal transection above the silastic ring and the trimming of the gastric pouch

thrombosis, patients received a daily subcutaneous injection with low-molecular-weight heparin for 14 days postoperatively together with elastic compression stockings. In addition, a proton pump inhibitor (PPI) (omeprazole 20 mg) was started and continued for 3 months (40 mg lifelong for smokers) to prevent marginal ulcer formation. The first follow-up visit was scheduled for 6 weeks. Thereafter, visits were planned after 6 months, after 12 months, and then annually.

#### Statistics

Statistical analysis was carried out using SPSS 15.0 software, continuous data was compared using Wilcoxon rank sum test and one-way ANOVAs. The BMI change was calculated using the mean  $\pm$  standard deviation. All statistical tests were two sided and results were considered statistically significant if  $p < 0.05$ .

#### Results

From Feb 2004 to Feb 2011 (85 months), 5,095 laparoscopic RYGB had been performed in our department. Of these, 153 patients were identified who had previous VBG and required

conversion to RYGB. The patient demographics are listed in Table 1. All these revisional operations were performed by a single surgeon or by other surgeons under his direct supervision. The short-term follow-up ( $\leq 30$  days) was complete for 153 patients (100 %), while the long-term follow-up data were complete for 142 out of the 153 patients (92.8 %).

The main indication for revisional surgery was insufficient weight loss  $\pm$  weight regain in 145 patients (94.8 %). Additionally, a substantial number of patients experienced one or more major GI symptoms, which was related to the developing gastric outlet obstruction. Intractable vomiting was present in 72/153 patients (47.1 %), reflux disease affected 56/153 patients (36.6 %), and solid food dysphagia affected 39/153 patients (25.4 %).

The initial VBG procedure had been performed an average of 5.37 (1.21–26.9) years prior to the conversion. In 123 patients, a laparoscopic VBG (MacLean) was performed; in 30 patients, an open VBG (Mason). The preoperative upper GI radiologic series demonstrated staple line dehiscence with resultant gastro-gastric fistula in three cases (all open VBG procedures) and 28 patients had already undergone some correction of their VBG; most of them a silastic ring removal.

#### Short-Term Follow-Up ( $\leq 30$ Days)

The mean hospital stay was 4.3 (3–10) days. There were no conversions to open surgery in our series and no leaks were observed. The mortality rate was zero.

Six patients (3.9 %) developed postoperative complications in the early postoperative period of whom two required reoperation. Two patients (1.3 %) had postoperative bleeding; one of them had imbalanced vital signs which necessitated re-laparoscopy and operative bleeding control 18 h post-RYGB. The other patient was successfully treated conservatively. One

patient showed signs of sepsis on day 3; she had a small paraduodenal collection on CT scan without any signs of anastomotic leakage. She was successfully treated with IV antibiotics without drainage. One patient developed type 2 respiratory failure post-procedure and required 96 h non-invasive (CPAP) ventilation, observation and multi-organ support on intensive care unit. Intraoperative pancreatic injury and subsequent pancreatitis occurred in one patient. This lesion was recognised during the procedure and a corrugated drain was left in situ. Under intensive conservative treatment (fluid resuscitation, IV Somatostatin) she recuperated well and could be discharged on day 8. Three days later, she was readmitted with a subcutaneous collection at the drain site which was drained percutaneously. A 64-year-old lady developed a left lateral port site hernia on postoperative day 28 with incarcerated omental fat. She underwent an emergency repair with resection of the herniated omental fat.

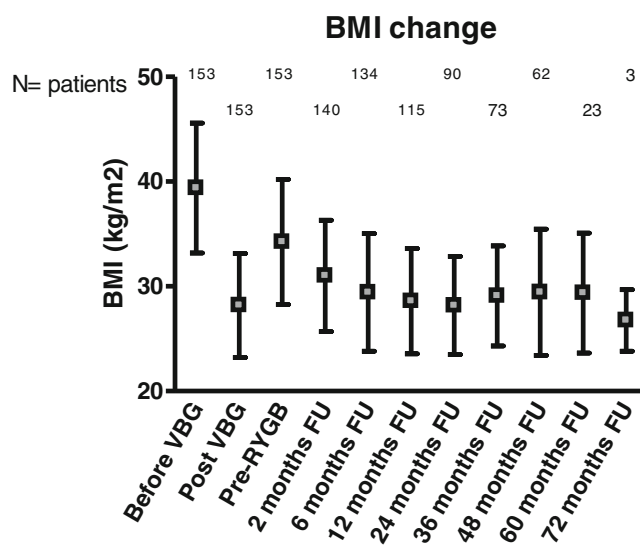
Three patients were readmitted; one patient for percutaneous drainage of a subcutaneous collection and one patient with an incarcerated left trocar site hernia (both described above). Another patient with postoperative pain and vomiting was readmitted on postoperative day 6 (48 h after discharge). Technical investigations did not reveal any abnormalities and the patient could leave the hospital 2 days later.

#### Long-Term Weight Loss Data

The initial VBG procedure resulted in a substantial weight loss with a decrease in mean BMI from 39.4 to 28.1  $\text{kg}/\text{m}^2$  (lowest post-VBG weight). The mean BMI increased to 34.2  $\text{kg}/\text{m}^2$  prior to the RYGB conversion (pre-RYGB). After a median follow-up of 48 (10–81) months, the mean BMI decreased significantly to 28.8  $\text{kg}/\text{m}^2$  ( $p < 0.05$ ). The BMI flow chart is shown on Fig. 3.

**Table 1** Patient demographics and preoperative co-morbidities

Demographics and perioperative data		
Variable		Patients (%)
Gender ( <i>n</i> )	Female	123 (80 %)
	Male	30 (20 %)
Age (year)	Mean	44.4
	Range	15–74
Length of stay (days)	Mean	4.31
	Range	3–10
Interval between VBG to RYGB (years)	Median	5.37
	Range	1.21–26.93
Preoperative co-morbidities:		
	Type 2 diabetes mellitus	19 (12.4 %)
	Hypertension	17 (11 %)
	Hypercholesterolaemia	18 (11.7 %)



**Fig. 3** Long-term BMI flow chart

## Long-Term Follow-Up

The median follow-up in our series was 48 (10–81) months. There was a complete resolution of the GI symptoms in a vast majority of the patients. The amelioration was already obvious in the early postoperative follow-up. Dysphagia completely resolved in all patients after the RYGB. Intractable vomiting also settled initially in all patients, but recurred in one patient who developed gastro-jejunostricture and required endoscopic dilatation (see below). GORD resolved in all but 3.5 % of the patients. The type 2 diabetes resolution was experienced in 79 % of the patients, while the hypertension improved in 70.6 % patients. Late complications developed in 11 patients (7.7 %) and seven patients (4.9 %) required surgery for correction. Internal hernia occurred overall in four patients (2.8 %). Two of them were treated laparoscopically in our hospital and both were herniations at the level of Petersen's space. Another two patients had internal herniation and underwent emergency laparoscopic operation in their local hospitals but no further details were available. A marginal ulcer was found and treated conservatively with high-dose PPI in three patients (2.1 %). In one patient, the ulcer was complicated by a stenosis of the gastro-jejunostricture which has been successfully dilated after complete healing of the ulcer. Two patients (1.4 %) developed a small bowel obstruction. In one, a laparoscopic adhesiolysis was performed. In the other patient, the ileus was treated conservatively. Ventral incisional hernia was found and operatively corrected in two patients (1.4 %; both with mesh repair).

Unsuccessful weight loss or weight regain occurred in eight patients (5.6 %). Dietary modification and behavioural counselling has been installed in all of them. Three of them had a re-operation. An adjustable gastric band was placed around the pouch in two patients to obtain food restriction and one patient had pouch reconstruction 5 years post conversion.

## Discussion

VBG is a restrictive bariatric surgical procedure, originally described by Mason in the early 1980s [8]. With the development of surgical endoscopic techniques, the open non-transected procedure evolved to a laparoscopic transected procedure as published by MacLean. Regardless of whether the surgical approach was open or laparoscopic, the initial short- and even medium-term results regarding weight loss were satisfactory as shown in two systematic reviews [17, 18]. However, as time progressed two long-term problems were noticed. First of all, a high proportion of patients now present with severe GI symptoms (dysphagia, vomiting, GORD) due to the progressive stenosis and/or kinking at the level of the initial placed ring or mesh. Secondly, and concomitant to the gastric outlet obstruction, a lot of patients develop maladaptive eating resulting in weight regain. This gastric outlet obstruction is relatively refractory to endoscopic dilation, necessitating a surgical correction in a high number of patients. Removal of the silastic ring or longitudinal section of the Dacron/Marlex mesh is a simple surgical option which provides good results in symptoms resolution. Hence, a full or partial restoration of the gastric continuity between the pouch and the gastric fundus is rarely indicated. However those procedures will inevitably lead to progressive weight regain. This is the reason why the majority of bariatric surgeons do prefer the immediate conversion from the VBG to another type of bariatric procedure. A wide variety of surgical revisional options has been described. In case of loss of restriction and in absence of gastric outlet obstruction, a re-VBG or a band on the VBG have been proposed [1, 19–24]. Nowadays though, there is growing concern whether it is rational and beneficial to change a purely restrictive procedure by another. The conversion from a VBG to a sleeve gastrectomy has been proposed by some authors [25–28]. Although the popularity and the

**Table 2** Early morbidity, reoperation and mortality rates published before

Author	N	Open/lap	Early morbidity rate	Early reoperation rate	Mortality rate
Van Gemert (1998) [34]	15	15/0	33 %	27 %	0 %
Nesset (2007) [35]	218	216/2	26 %		0.9 %
Mognol (2007) [36]	24	11/13	16.7 %	4.2 %	0 %
Ianelli (2008) [37]	18	1/17	22.2 %	5.5 %	0 %
Marsk (2009) [6]	49	11/38	12.2 % (leak rate)	6.1 %	0 %
Cariani (2010) [19]	60	60/0	6.5 %	0 %	0 %
Gagné (2011) [33]	105	0/105 (one hand ass)	19 %	4.8 %	0 %
Tevis (2011) [1]	25	21/4	29 % (open group) 25 % (lap group)	NA	NA
Suter (2012) [31]	203	0/203	11.8 %	4.4 %	0.5 %

Early morbidity and mortality rates on conversion of VBG to RYGB



indications for the gastric sleeve are increasing rapidly, surgeons should be very cautious in considering a sleeve as a revisional procedure for a VBG. In association with the higher intraluminal gastric pressure after a sleeve, transecting the stomach in close vicinity of the ring/mesh and surrounding scar tissue, may pose a higher risk of postoperative leak and should therefore be avoided. The same is true for conversion of a VBG to a duodenal switch.

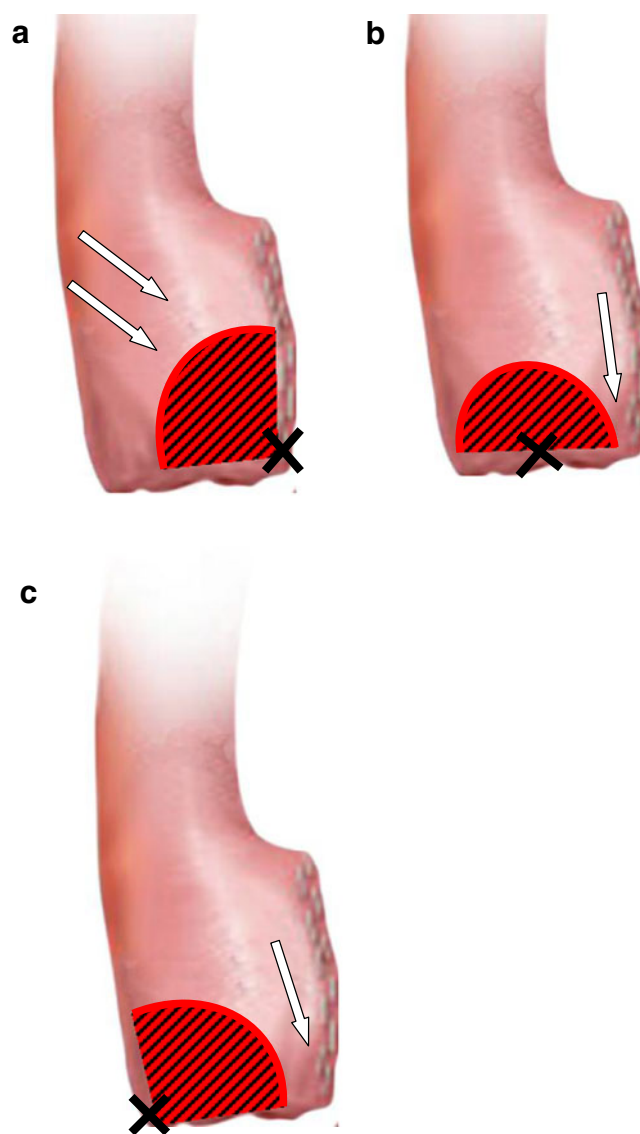
The RYGB is generally accepted as the gold standard surgical weight loss procedure with excellent results both in terms of weight loss and quality of life. Although, its place is now well recognised in the bariatric field as a primary procedure, there is also a steep increase in the number of RYGB procedures performed as a secondary revisional procedure after other previous failed procedures. The main reason for this is the technical suitability of the procedure which combines mainly food restriction with malabsorption and hormonal action mechanisms, resulting in further weight decrease and resolution of associated symptoms.

Nevertheless, revisional bariatric surgery including RYGB is technically challenging and is associated with a higher complication and mortality rate in comparison with a primary procedure [29]. The group of Cadière et al. recently reported gastro-jejunal leaks in 6 of 43 patients (14 %) after conversion of VBG to RYGB [30].

Table 2 gives an overview of other published series on conversion of VBG to RYGB respectively with their early morbidity, reoperation and mortality rates. In our series, the early complication rate was low (3.9 %) and comparable to the complication rate we reported in 2,606 mainly primary RYGB [15].

Apart from our fully stapled and standardized technique of RYGB, we believe that some other more specific and individually patient-tailored surgical technical refinements are crucial in achieving a low complication rate, especially leak rate. We always construct our new gastric pouch by horizontally transecting the stomach well above the location of the scar tissue surrounding the ring/mesh. Even in the case of high positioned rings or meshes, we still were able to leave a small gastric pouch in order to perform a gastro-jejunostomy instead of an esophagojejunostomy. The latter is probably technically more hazardous and annihilates—at least theoretically—the presumed neurological pathways between the stretch receptors in the gastric pouch and the cerebral appetite centres (in the hypothalamus). However, Suter et al. recently showed good results with these types of anastomoses in terms of postoperative morbidity as well as on weight loss on the long term [31]. Because of chronic distension of the gastric pouch in the majority of patients, the gastric wall is substantially thicker than in primary bypass, compelling the use of the highest staple height (4.8 mm or higher) in safely transecting the stomach tissue. The gastrojejunostomy itself can be performed in three

manners: with a linear stapler, circular stapler or hand-sewn. We (still) prefer the circular stapled one for which we use on a standardized fashion a 25-mm circular stapler (mostly 4.8-mm staple height), brought in transabdominally through a left dilated (trocar) incision. The anvil is always inserted through a small opening in the left lateral corner of the pouch thereby ensuring a wide inflow of vascularisation from the ventral and dorsal side of the gastric pouch. Inserting the anvil through an opening in the medial corner or in the middle of the horizontal staple line will compromise more the vascularisation of the gastric pouch tip distal and lateral where some gastric tissue could become entrapped



**Fig. 4** Creation of the circular stapled gastro-jejunostomy. **a** Insertion of the circular stapler in the left lateral corner preserves a wide inflow of vascularisation (*two white arrows*). Insertion of the circular stapler in the middle (**b**) or in the medial corner (**c**) of the horizontal staple line can induce ischaemia at the indicated *arrows*

between two staple lines (Fig. 4). The latter is also a known risk point in making a linear stapled anastomosis.

Also, upper GI series play an important key role in the surgical decision making since the most frequent complications can preoperatively be detected in this way [32].

When constructing the gastric pouch, one should always pay attention to carefully indentify the old staple lines both on the front and on the backside of the stomach. This is necessary during pouch creation in a previous Mason procedure (non-transected), but also if a pouch trimming is carried out in a former laparoscopic transected VBG. The reason for this is to prevent mucocoele formation and possible ischemia between the 'new' staple line and the 'old' one. Therefore, in all cases, we resect the old staple line and in case of a Mason conversion, an additional partial gastrectomy with resection of the fundus is performed including both staple lines.

We always test the gastrojejunal anastomosis by performing a firm methylene blue leak test via the orogastric tube at the end of the procedure. This simple and non-time-consuming test will help the surgeon to intraoperatively detect an anastomotic failure and to correct this immediately with additional sutures if necessary.

Some reports have evaluated the long-term results in terms of weight loss, resolution of GI symptoms and complications in series converting VBG to RYGB. The largest single-institution-based retrospective study analysed 105 patients, who had failed VBG converted to RYGB laparoscopically. In this study, the patients experienced not only significant weight loss (8 kg/m<sup>2</sup>), but 95 % of the GORD symptoms and 100 % of the dysphagia resolved [33]. This study mainly focuses on the redo after primary open procedure (103/105 open cases). In contrast, in our study, most of the patients underwent a laparoscopic VBG. The results of our study showed that laparoscopic revision of VBG to RYGB provides acceptable weight loss, resolution of symptoms related to gastric outlet obstruction and a substantial improvement of weight-related co-morbidities. However, we have to take into account that late complications occurred in 7.7 % of our patients in which in 4.9 % surgery was necessary for correction, and in eight patients (5.6 %) there was unsuccessful weight loss post-RYGB in which three patients required a third bariatric intervention.

## Conclusion

To our knowledge, this series on 153 patients is the largest single-centre experience on laparoscopic conversion of VBG to RYGB. This study demonstrates that those conversions are possible with a low short-term complication and reoperation rate. On the long term, there is almost a complete resolution of the symptoms related to gastric outlet obstruction and a statistically significant positive impact on

the patients' body weight. We recommend RYGB as the procedure of choice in those requiring revisional surgery following VBG.

**Conflict of Interest** All authors declare no conflict of interest.

## References

1. Tevis S, Garren MJ, Gould JC. Revisional surgery for failed vertical-banded gastroplasty. *Obes Surg*. 2011;21(8):1220–4.
2. Balsiger BM, Poggio JL, Mai J, et al. Ten and more years after vertical banded gastroplasty as primary operation for morbid obesity. *J Gastrointest Surg*. 2000;4(6):598–605.
3. Baltasar A, Bou R, Arlandis F, et al. Vertical banded gastroplasty at more than 5 years. *Obes Surg*. 1998;8(1):29–34.
4. Miller K, Pump A, Hell E. Vertical banded gastroplasty versus adjustable gastric banding: prospective long-term follow-up study. *Surg Obes Relat Dis*. 2007;3(1):84–90.
5. Scozzari G, Toppino M, Famiglietti F, et al. 10-year follow-up of laparoscopic vertical banded gastroplasty: good results in selected patients. *Ann Surg*. 2010;252(5):831–9.
6. Marsk R, Jonas E, Gartzios H, et al. High revision rates after laparoscopic vertical banded gastroplasty. *Surg Obes Relat Dis*. 2009;5(1):94–8.
7. Schouten R, Wiryasaputra DC, van Dielen FM, et al. Long-term results of bariatric restrictive procedures: a prospective study. *Obes Surg*. 2010;20(12):1617–26.
8. Mason EE. Vertical banded gastroplasty for obesity. *Arch Surg*. 1982;117(5):701–6.
9. MacLean LD, Rhode BM, Forse RA. A gastroplasty that avoids stapling in continuity. *Surgery*. 1993;113(4):380–8.
10. Mason EE, Cullen JJ. Management of complications in vertical banded gastroplasty. *Curr Surg*. 2003;60(1):33–7.
11. Yale CE. Conversion surgery for morbid obesity: complications and long-term weight control. *Surgery*. 1989;106(3):474–80.
12. Behrns KE, Smith CD, Kelly KA, et al. Reoperative bariatric surgery. Lessons learned to improve patient selection and results. *Ann Surg*. 1993;218(5):646–53.
13. Hunter R, Watts JM, Dunstan R, et al. Revisional surgery for failed gastric restrictive procedures for morbid obesity. *Obes Surg*. 1992;2(3):245–52.
14. Capella RF, Capella JF. Converting vertical banded gastroplasty to a lesser curvature gastric bypass: technical considerations. *Obes Surg*. 1998;8(2):218–24.
15. Dillemans B, Sakran N, Van CS, et al. Standardization of the fully stapled laparoscopic Roux-en-Y gastric bypass for obesity reduces early immediate postoperative morbidity and mortality: a single center study on 2606 patients. *Obes Surg*. 2009;19(10):1355–64.
16. Mulier JP, Dillemans B, Van CS. Impact of the patient's body position on the intraabdominal workspace during laparoscopic surgery. *Surg Endosc*. 2010;24(6):1398–402.
17. Buchwald H, Avidor Y, Braunwald E, et al. Bariatric surgery: a systematic review and meta-analysis. *JAMA*. 2004;292(14):1724–37.
18. Buchwald H, Estok R, Fahrenbach K, et al. Trends in mortality in bariatric surgery: a systematic review and meta-analysis. *Surgery*. 2007;142(4):621–32.
19. Cariani S, Agostinelli L, Leuratti L, et al. Bariatric revisionary surgery for failed or complicated vertical banded gastroplasty (VBG): comparison of VBG reoperation (re-VBG) versus Roux-en-Y gastric bypass-on-VBG (RYGB-on-VBG). *J Obes* 2010; 2010.

20. Thill V, Khorassani R, Ngongang C, et al. Laparoscopic gastric banding as revisional procedure to failed vertical gastroplasty. *Obes Surg.* 2009;19(11):1477–80.
21. Dargent J. Lap banding as a redo surgery: “restriction over restriction” may be a relevant bariatric strategy. *Obes Surg.* 2009;19(9):1243–9.
22. Taskin M, Zengin K, Unal E, et al. Conversion of failed vertical banded gastroplasty to open adjustable gastric banding. *Obes Surg.* 2001;11(6):731–4.
23. Gavert N, Szold A, bu-Abeid S. Laparoscopic revisional surgery for life-threatening stenosis following vertical banded gastroplasty, together with placement of an adjustable gastric band. *Obes Surg.* 2003;13(3):399–403.
24. Wenger M, Piec G, Branson R, et al. Salvage of gastric restriction following staple-line dehiscence after vertical banded gastroplasty by insertion of an adjustable gastric band. *Obes Surg.* 2005;15(2):216–22.
25. Foletto M, Prevedello L, Bernante P, et al. Sleeve gastrectomy as revisional procedure for failed gastric banding or gastroplasty. *Surg Obes Relat Dis.* 2010;6(2):146–51.
26. Iannelli A, Schneck AS, Ragot E, et al. Laparoscopic sleeve gastrectomy as revisional procedure for failed gastric banding and vertical banded gastroplasty. *Obes Surg.* 2009;19(9):1216–20.
27. Berende CA, de Zoete JP, Smulders JF, et al. Laparoscopic sleeve gastrectomy feasible for bariatric revision surgery. *Obes Surg.* 2012;22(2):330–4.
28. Jacobs M, Gomez E, Romero R, et al. Failed restrictive surgery: is sleeve gastrectomy a good revisional procedure? *Obes Surg.* 2011;21(2):157–60.
29. Cariani S, Nottola D, Grani S, et al. Complications after gastroplasty and gastric bypass as a primary operation and as a reoperation. *Obes Surg.* 2001;11(4):487–90.
30. Cadiere GB, Himpens J, Bazi M, et al. Are laparoscopic gastric bypass after gastroplasty and primary laparoscopic gastric bypass similar in terms of results? *Obes Surg.* 2011;21(6):692–8.
31. Suter M, Ralea S, Millo P, et al. Laparoscopic Roux-en-Y gastric bypass after failed vertical banded gastroplasty: a multicenter experience with 203 patients. *Obes Surg* 2012 June 15.
32. Sadeghi N, Closset J, Houben JJ, et al. Silicon ring vertical gastroplasty for morbid obesity: spectrum of radiologic findings. *AJR Am J Roentgenol.* 2000;175(1):135–9.
33. Gagne DJ, Dovec E, Urbandt JE. Laparoscopic revision of vertical banded gastroplasty to Roux-en-Y gastric bypass: outcomes of 105 patients. *Surg Obes Relat Dis.* 2011;7(4):493–9.
34. van Gemert WG, van Wersch MM, Greve JW, et al. Revisional surgery after failed vertical banded gastroplasty: restoration of vertical banded gastroplasty or conversion to gastric bypass. *Obes Surg.* 1998;8(1):21–8.
35. Nessel EM, Kendrick ML, Houghton SG, et al. A two-decade spectrum of revisional bariatric surgery at a tertiary referral center. *Surg Obes Relat Dis.* 2007;3(1):25–30.
36. Mognol P, Chosidow D, Marmuse JP. Roux-en-Y gastric bypass after failed vertical banded gastroplasty. *Obes Surg.* 2007;17(11):1431–4.
37. Iannelli A, Amato D, Addeo P, et al. Laparoscopic conversion of vertical banded gastroplasty (Mason MacLean) into Roux-en-Y gastric bypass. *Obes Surg.* 2008;18(1):43–6.